

Surgery and Tinnitus for Otosclerotic Patients

Jean-Bernard Causse, M.D., Robert Vincent, M.D.

Jean Causse Clinic, Traverse de Béziers, Béziers, France

Abstract: In our experience, tinnitus for otosclerosis may be due to the following: poor vibration of the inner ear fluids, fixation of the footplate, destruction of the Corti hair cells by the proteolytic enzymes, acoustic trauma, or to poor inner ear blood supply due to the hyalinization of the spiral ligament of the stria vascularis. The aim of this article is to suggest some explanations to enhance future research work carried out by other authors on this important issue, and to show what are the results of surgery in our experience, as far as tinnitus is concerned. Only complete release of the tinnitus one year after surgery is taken into account to assess the results.

Key Words: Otosclerosis, Tinnitus

INTRODUCTION

Otosclerosis is first of all a regrowth of pseudo-haversian bone fixing the footplate of the stapes. The annular ligament of the footplate is progressively invaded by new bone. The annular ligament of the footplate is an elastic bank of 0.2 mm surface surrounding the footplate.¹ The elastic fibers give the required elasticity needed for a proper vibration of the footplate. Otosclerosis and footplate fixation results in poor vibration of the inner ear fluids and contributes to tinnitus.

PHYSIOLOGIC CONSIDERATIONS

1. Acoustic impedance; stapes footplate mobility; annular ligament elasticity

The following formula shows the acoustic impedance of the annular ligament of the footplate. The annular ligament of the footplate is the only part of the ossicular chain which is involved by the otosclerotic foci (Fig. 1).

$$Z = \sqrt{R^2 + \left(2\pi f \cdot M - \frac{S}{2\pi f}\right)^2}$$

Fig. 1 Acoustic impedance of the annular ligament of the stapes footplate

- Z = total resistance of the annular ligament to acoustic vibration.
 R = resistance of the annular ligament, sort of shock absorber, protecting the inner ear against acoustic trauma and baro-trauma.
 M = mass of the ossicular chain applied to the annular ligament of the footplate. It plays a role for high pitched frequencies as multiplied by frequency.
 S = elasticity of the annular ligament of the footplate: kind of spring or trampoline effect; it plays a role for low tones (up to 3 kHz) as divided by frequency, as far as the quality and the quantity of hearing is concerned.
 f = frequency of the vibration of the annular ligament.

2. Surgery - Footplate

When the fixed stapes is replaced by a piston and a piece of vein graft the vibration of the part of the piece of vein graft located between the piston, replacing the stapes crura, and the edge of the hole made in the footplate, plays the role of sort of a new annular ligament. The hole in the footplate should be 0.8 mm, and the piston 0.4 mm, in order that 0.2 mm piece of vein graft is to say "elastic fibers".

When the elastic band is replaced by bone, the resistance increases and the elasticity decreases, leading to an

increase in the acoustic impedance of the ossicular chain. This increase in the resistance of the acoustic vibration of the annular ligament of the stapes footplate makes the inner ear fluids vibrate less, mainly for the low tones. The audiometric gap is larger for the low tones. Thus the vibration of the membranes and hair cells is decreased. The JB Causse schematization of inner ear function² proposes that the internal inner ear Corti hair cells carry the message to the brain, whereas the external ones bring the message from the brain to the inner ear in order to help select the "keynotes", amplifying the message or buffering it (Fig.2).

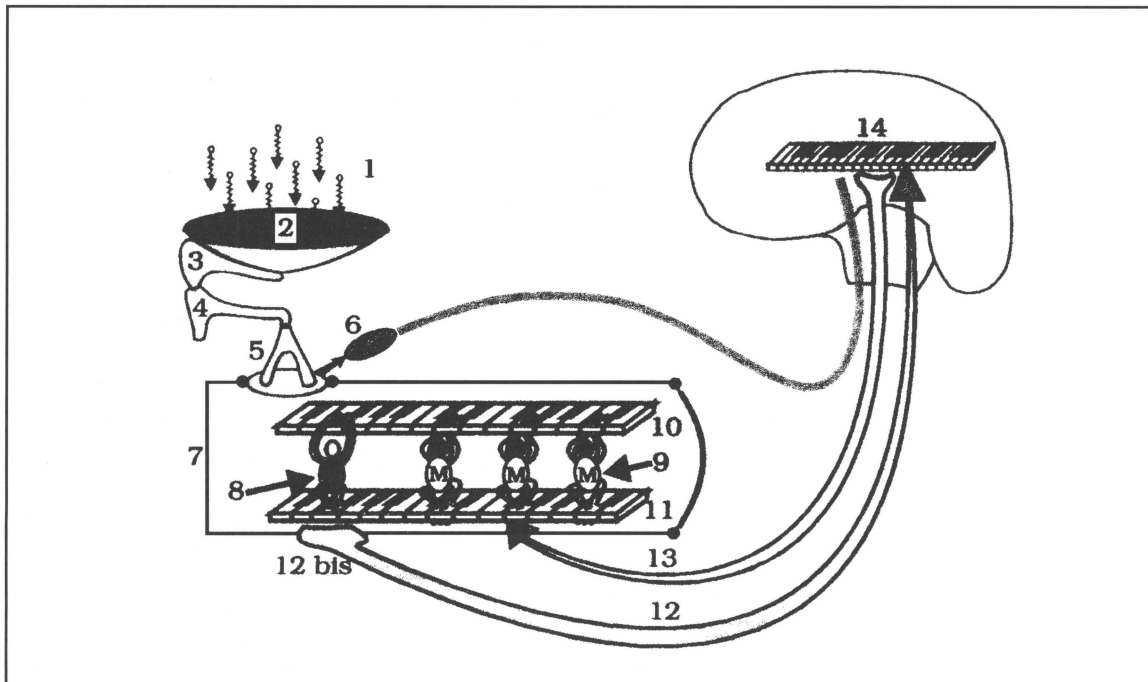


Fig. 2. Schematization of Inner Ear Function (J. B. Causse)

- 1 = vibration of the air particles
- 2 = tympanic membrane: sort of drum
- 3 = malleus
- 4 = incus: sort of record player arm
- 5 = stapes: sort of needle of the record player
- 6 = stapes tendon
- 7 = cochlea
- 8 = internal Corti hair cells: palpate the keynotes on the keyboard with keynotes on the tectorial membrane
- 9 = external Corti hair cells attached to the tectorial membrane in order to select the keynotes, buffer or amplify them
- 10 = tectorial membrane
- 11 = basilar membrane
- 12, 13, 14 = this keyboard arrangement helps selecting the keynotes, amplifying the message and mainly buffering it.

THEORY INNER EAR FUNCTION

When less information gets to the brain, the brain has the tendency to increase the information to the external Corti hair cells located near the hair cells which are destroyed (border line),³ leading to excessive muscular action on the membranes. The external Corti hair cells are attached to the tectorial membrane located above them. They contain actine and myosine. This excess bio-feedback message leads to low tone tinnitus most of the time, compared by the patient to a buzzing or an engine-like noise.

When the fixed stapes is properly replaced by a piston, with an interposition of a piece of vein graft to enhance the good elasticity of the system,¹ the vibration of the inner ear fluids is good, and this bio-feedback vicious circle stops immediately; the tinnitus is completely released.

When surgery allows a good vibration of the inner ear fluids, it will stop low tone tinnitus. Poor inner ear fluid vibration e.g. obstruction of the external ear canal, perforation of the tympanic membrane, fixation of one of the ossicles, incus necrosis, glue ear, etc., may cause low tone tinnitus to exist. Efficient surgery will make the tinnitus disappear.

When the reconstruction of the middle ear is followed by fibrous tissue formation located between the long process of the incus and the promontory, the piston pushes into the vestibule. The resultant increase in pressure of the labyrinthine fluids may, as in a hydrops, create low tone tinnitus. If the tinnitus at the time of the revision surgery is still of the low tones only, it will disappear completely after revision surgery of the middle ear. If the tinnitus is located in the high pitched frequencies 6 and 8 kHz, the Corti hair cells degeneration is most of the time an irreversible damage. If a few days after revision surgery, no results are shown for the disappearance of the tinnitus then it is too late to hope for a further disappearance of the tinnitus.

PROTEOLYTIC ENZYMES DESTRUCTION OF THE CILIA OF THE CORTI HAIR CELLS

Proteolytic enzymes are released from the otosclerotic foci.⁴⁻⁶ The proteolytic enzymes are able to destroy the proteins of the Corti hair cells.⁴⁻⁶ The frequencies involved in the destruction of the Corti hair cells are those located about the 2 kHz as demonstrated by Linthicum and Parahy.⁷ The enzymatic hearing loss notch on the audiogram will be about the 2 kHz (Carhart notch) and the tinnitus will be located about the same frequency. Sodium fluoride is able to arrest the activity of the

proteolytic enzymes,⁸⁻¹⁰ but will not help to rebuild the structures of the destroyed hair cells. Sodium fluoride will help to avoid an increase in tinnitus located about the 2 KHz but will not help diminishing its intensity. As a matter of fact, the Carhart notch about the 2 kHz is only partly due to the enzymatic process. It is mainly due to the fixation of the footplate. This is the reason why post-operatively, in two-third of the cases, the tinnitus, located about mid-frequencies, are much less after surgery. There is no reliable test before surgery that may indicate if the tinnitus is predominantly due to a poor vibration of the fluids or if they have an enzymatic origin.

ACOUSTIC TRAUMA

Acoustic traumas are able to damage the inner ear hair cell structures, all the more so since the proteolytic enzymes have already partially destroyed the protein structure of the Corti hair cells. Thus, an acoustic trauma will put an otosclerotic patient in greater danger than a normal person. Poor vibration of the inner ear fluids does not involve a high pitched frequency. This is the reason why surgery for otosclerosis will not relieve the tinnitus located in the high tones.

Prevention against acoustic trauma is considered of paramount importance to an otosclerotic patient. Acoustic trauma may disconnect the attachment between the cilia of the external Corti hair cells, as explained in the theory of Tonndorf (1980)³ leading to an epilepsy-like message to the brain. The external Corti hair cells are not able to buffer the message sent to the internal Corti hair cells. According to Remy Pujol,¹¹ there is an increase in the amount of glutamate neuro-transmitter at the synapse between the internal Corti hair cell and the first neuron. The increase in the amount of glutamate is not only the cause of the tinnitus, but is also the cause of the destruction of the synapse, leading to deafness. The role of the medial lateral efferent system offers hope for the treatment of this kind of tinnitus.¹¹

POOR INNER EAR BLOOD SUPPLY

Poor inner ear blood supply, due to the hyalinization of the spiral ligament of the stria vascularis by the proteolytic enzymes,¹² leads to a lack of glucose and oxygen to the Corti hair cells. The same theories as applied to the degeneration of the Corti hair cells by acoustic trauma, help to understand the mechanism of the tinnitus due to poor inner ear blood supply. The surgery is of course inefficient to help curing 6 to 8 kHz high pitched tinnitus. Vascular drugs separating the platelets and red cells are useful, as well as those that will help to change the shape of the red cells.¹³

RESULTS

Experience with Otosclerosis Surgery

Experience shows that tinnitus in otosclerotic patients when it is low tone is likely to be decreased following stapes surgery.

We have performed a statistical retrospective study, comparing pre-operative and post-operative tinnitus patients one year after surgery.

We studied the tinnitus in otosclerotic patients according to their frequency and intensity.

The intensity and frequency were assessed by the audiometrist the day before and one year after surgery, by comparing the tinnitus with a pure tone sound emitted by the audiometer and heard by the opposite ear of the patient.

As far as intensity, the tinnitus patients before surgery were at the level of the hearing loss, or 5 to 15 dB above that threshold.

As far as the disappearance of the tinnitus one year after surgery, and in order to avoid excessive subjectivity of the patients, the complete disappearance of the tinnitus was the only criterion for success.

Out of more than 49,000 patients operated on between 1961 and 1993 in the J. Causse Clinic, we have selected only 643 patients, in order to be sure that the selected ones had no disease other than otosclerosis; were between 30 and 50-years of age; had surgery by the same surgeon (i.e., JB Causse); and had the JB Causse technique performed⁹ (rebuilding as much as possible the impedance transfer and the acoustic impedance of the ossicular chain).

FREQUENT QUESTIONS AND ANSWERS

Question N° 1:

When do patients report improvement in the low frequency tinnitus? Immediately, at the time of surgery, hours, days, weeks, or months later etc?

Answer:

The patient reports improvement in the low frequency tinnitus as soon as the wick is removed a few days after surgery. If it is not improved immediately, it will not be improved later on.

Question N° 2:

What was the character of the recovery? Immediate, gradual?

Answer:

The recovery is immediate and not gradual; for the low tones the recovery is complete.

Question N° 3:

What have you found to be the correlation between the tinnitus recovery to the extent of the otosclerosis? To the use of sodium fluoride pre-, post-surgery? Any statistical difference(s) or significances?

Answer:

There is no correlation between the fixation of the footplate compared to the loudness of the tinnitus. Only if the tinnitus is of the low tones, will the patient have a real chance to have tinnitus disappear. The higher the tinnitus frequency the less chance we have seen for tinnitus to disappear after surgery.

Question N° 4:

You imply that the low frequency tinnitus is a cochlear tinnitus. Why not say this experience reflects the clinical impression that there are different clinical types of tinnitus of which the low frequency tinnitus in otosclerosis is a cochlear type?

Answer:

Low frequency tinnitus is a cochlear tinnitus only by the location. But, as a matter of fact, they are mechanical as the poor vibration of the inner ear fluids gives a poor vibration of the internal inner ear hair cells leading to probable extra-stimulation of the external Corti hair cells. As the cause can be treated by surgery, that is the reason why the low tones tinnitus disappear. The problem is purely mechanical. The disappearance of the tinnitus must be compared to the improvement of the bone conduction on the low and mid frequencies after surgery. The bone conduction improves because of a better vibration of the inner ear fluids, and thus better vibration of the inner ear hair cells. That is the reason why Itard and Valsalva by inflating the middle ear produced a better function of the ossicular chain and could also decrease the low tone tinnitus in some patients.

Question N° 5:

What percentage of patients experience complete tinnitus relief one year following surgery?

Answer:

The following shows the percentage of patients experiencing a complete release from tinnitus one year after surgery:

	Patients Percentage
500 Hz	77.8 %
2 kHz	38.4 %
4 kHz	11.3 %
8 kHz	2.9 %

CONCLUSIONS

In our experience, surgery for tinnitus due to otosclerosis can help tinnitus of the low tones. The more the tinnitus is of low pitched frequencies before surgery, the more effective will surgery be for tinnitus relief.

REFERENCES

1. Wiet RJ, Causse JB, Shambaugh GE, Causse JR: Monograph on otosclerosis. The American Academy of Otolaryng-HNS Foundation, Alexandria, VA, 1991.
2. Causse JB: Acoustique au fin fond de l'oreille une leçon de piano - Extrait d'Isolation Informations, 187, Comité Français de l'Isolation, Paris, Février, 1994.
3. Geoffroy B: Acouphenes, Monographie -Laboratoire IPSEN.
4. Causse JR, Chevance LG, Uriel J: Cellular and enzymatic concept of otospongiosis: cyto-clinical relationship. Proceedings of the Tenth World Congress, Venice, *Excerpta Medica Intern. Congress Series* 337:376-381, 1973.
5. Causse JR, Causse JB: L'otospongiose, maladie familiale. Sa détection précoce, son traitement médical, *Am J Otol (Paris)*, 97:325-351, 1980.
6. Causse JR, Causse JB: Otospongiosis as a genetic disease. Early detection, medical management and prevention. *Am J Otol* 5:211-223, 1984.
7. Parahy C, Linthicum FH: Otosclerosis and otospongiosis. Clinical and histological comparisons. *Laryngoscope* 94:508-512, 1984.
8. Causse JR, Shambaugh GE, Causse JB, Bretlau P: Enzymology of otospongiosis and NaF therapy. *Am J Otol* 1:206-213, 1980.
9. Causse JR, Causse JB: Note thérapeutique concernant l'utilisation du fluorure de sodium dans l'otospongiose *Les Cahiers d'Otolaryngol*, 15:427-435, 1980.
10. Causse JR, Causse JB, Uriel J, et al: Sodium fluoride therapy. *Am J Otol*, 14-5:482-490, 1993.
11. Pujol R, Puel JL, Gervais D'aldin C, Eybalin M: Pathophysiology of the glutamatergic synapses in the guinea pig cochlea. *Acta Otolaryngol*, 113:330-334, 1993.
12. Parahy CH, Linthicum FH: Otosclerosis. Relationship of spiral ligament hyalinization to sensorineural hearing loss. *Laryngoscope* 93:717-720, 1983.
13. Causse JB, Authié D, Cauquil J: Iskedyl* et otospongiose: étude clinique - Extrait de la *Gazette Médicale*, 97.2:19-25, 1988.