

Gentamicin Cures Vertigo, but What Happens to Hearing?

Lars Ödkvist, M.D., Ph.D.

ENT Department, University Hospital, S-581 85 Linköping, Sweden

Abstract: Instillation of gentamicin in the middle ear to cure severe Meniere's disease is of considerable value in the control of vertigo. The drug causes diminished endolymph production and, most often, a peripheral vestibular loss. After vestibular rehabilitation, led by a physiotherapist, the ataxia should be resolved as a result of central compensation. Fifteen to twenty percent of the patients experience an added hearing loss in the treated ear, although this percentage is reduced if the treatment is given as a single instillation on 2 consecutive days. Using this strategy, the mean added hearing loss for the treated group is zero. There is no correlation between the pretreatment hearing level and the added hearing loss.

Keywords: Meniere's Disease; vertigo; gentamicin; hearing

Meniere's disease is characterized by a combination of fluctuating hearing loss and the presence of aural fullness, tinnitus, and intense rotatory vertigo attacks. The attacks are accompanied by intense nystagmus, which often changes direction during an attack. During the initial attacks, a hearing loss can usually be unveiled with pure-tone audiometry and, during the periods between attacks, the hearing may return to normal. As a rule, the vertigo attacks are present for some time and then absent for a longer period of months or even years. After several years and many attacks, the hearing loss does not return to normal between attacks. Often, the end result is an ear with a pure-tone threshold of 60–80 dB and very low speech discrimination. Very often, one finds that the vertigo attacks cease at the same time.

Conservative treatment, including a low-salt diet and the regulation of internal medical disorders, a stress-free life, and pharmacological therapy may help some patients such that no further treatment is necessary. However, if conservative treatment is unsuccessful, pressure treatment or an endolymphatic shunt operation may be necessary. Some patients with Meniere's disease reach a state of repeated severe vertigo attacks that diminish the quality of life. In those instances, sur-

gical sectioning of the vestibular nerve may be helpful, though this type of surgery carries some risks for damage to hearing and to the facial nerve and even the intracranial structures.

Ototoxic treatment in the middle ear offers a relatively safe way to treat this disabling form of Meniere's disease, carrying with it only the risk of damage to one's hearing ability. Gentamicin intratympanic treatment for Meniere's disease was developed by Lange, [1–3] and later used by Beck and Schmidt [4] and Ödkvist et al. [5].

MATERIALS AND METHODS

Since 1980, sixty-nine patients with a disabling form of Meniere's disease have been treated with gentamicin instillation in the middle ear. All had been treated with a salt-free diet and diuretics and, in some cases, other drugs. Four had been operated on using the shunt method and had experienced relapse of the disease process. Ten of the patients had been treated with pressure-chamber therapy but either had not responded or had suffered a relapse. To exclude other lesions in the internal meatus and the posterior fossa, imaging studies were performed with magnetic resonance imaging or computed tomography. Patients were fully informed so that they understood the concept of a unilateral vestibular loss and the central compensation enhanced by rehabilitation.

During the period 1980–1988, gentamicin was instilled daily through the tympanic membrane until there

Reprint requests: Lars Ödkvist, M.D., Ph.D., ENT Department, University Hospital, S-581 85 Linköping, Sweden. Fax: 46 13 222504; E-mail: Lars.Odkvist@oto.us.lio.se

plantation, Patient 7 suffered from Meniere's disease in the left ear. Since then, his average hearing threshold in the left ear has been approximately 60 dB. Patient 7 underwent endolymphatic shunt surgery in the left ear at another hospital in February 1997. However, no hearing improvement was attained. In July 1997, we treated the left ear with electrical promontory stimulation for tinnitus relief. Surprisingly, hearing loss in the left ear recovered to the nearly normal level after this treatment, as shown in Figure 5. Then tinnitus disappeared. This improvement matches that in the right ear. The hearing threshold in the right ear remains within normal limits. Nonetheless, the mechanism of hearing improvement in both ears is unclear.

Previously, an articulation test of grammatically correct but nonsense Japanese four-segment sentences improved after electrical stimulation of the ear. This was observed in both unstimulated and stimulated ears [14]. Therefore, improved hearing after electrical stimulation may be due to improved cognitive processing in the central auditory system in addition to improved hearing at the cochlea.

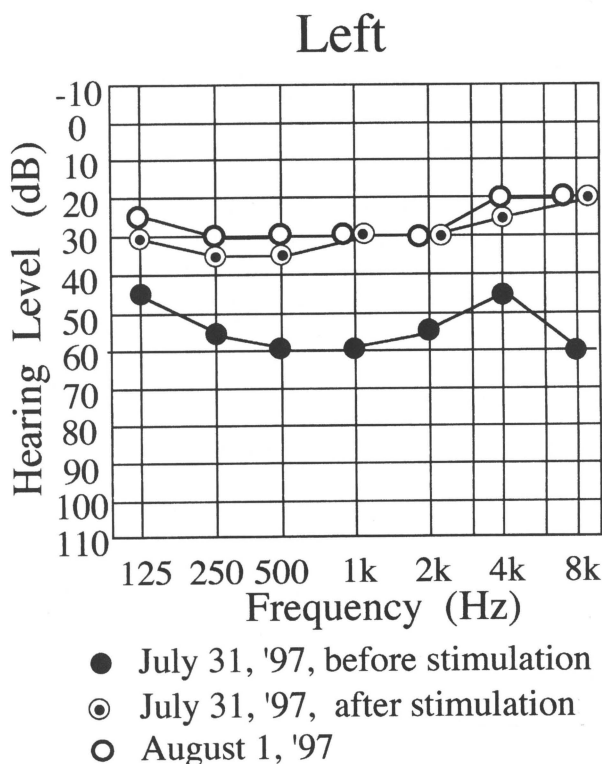


Figure 5. Hearing threshold in left ear of Patient 7 after electrical promontory stimulation. Thresholds were recorded on July 31, 1997, before stimulation; again on that day, approximately 45 minutes after electrical promontorium tympani stimulation; and on August 1, 1997, a day after stimulation. Note that the hearing threshold improved after electrical promontory stimulation.

The side on which the device is implanted is very important, especially in bilateral tinnitus patients. For ipsilateral tinnitus patients, the side of implantation was the ear having the worst hearing threshold. Hence, the suppressor was implanted in the ear with tinnitus in patients 2 and 7 because the hearing threshold in that ear was worse than that of the other ear. In Patient 1, the hearing threshold in the left ear (with tinnitus) was better than that of the right ear (without tinnitus), as shown in Figure 1. In addition, this patient uses a hearing aid in the left ear because hearing in her right ear is too poor to benefit from hearing aid use. We, therefore, implanted the suppressor in her right ear. Before the operation, we ascertained that electrical stimulation of the right ear (without tinnitus) made tinnitus disappear from the left ear. The result in Patient 1 after the implant operation was the same as that at outpatient clinics.

Bilateral tinnitus was reported in four patients. Here too the side of implantation was selected according to the degree of hearing loss. For example, in Patient 4, the intensity of tinnitus was the same in both ears, but the hearing level of the right ear was slightly worse than that of the left ear. Hence, we selected the right ear for the implantation. In bilateral tinnitus patients, the effect on tinnitus in ears without the implant is very encouraging. Tinnitus in the ear opposite the site of implantation in patients 4 and 5 disappeared completely postoperatively. Likewise, tinnitus at the unimplanted side sometimes disappeared in Patient 3 after the operation. In Patient 6, whose tinnitus did not disappear at outpatient clinics, tinnitus in both ears did not disappear but did improve after the operation. This finding proved that tinnitus is suppressed at the central auditory system.

Surprisingly, no patient in the present study perceived auditory sensation at 300 μ A. However, Shulman [5] reported that electrical stimulation with trans-tympanic electrode placement produced a sensation of vibration, auditory perception, electrical masking, tinnitus suppression, and pain. According to a sensagram proposed by Shulman [5], auditory sensation was preceded by tinnitus suppression. Shulman [5] also suggested that the most desirable outcome is to attain the tinnitus suppression threshold before auditory sensations are experienced. According to his theory, our patients with implantable devices are the most desirable candidates for electrical suppression of tinnitus. Therefore, we should select patients whose tinnitus suppression threshold is lower than that of the auditory sensation threshold for the implantation.

We used a 10-kHz sinusoidal wave for a carrier frequency because of the efficacy of the magnetic conduction system [15]. We compared the burst wave of a 10-kHz frequency with the continuous sinusoidal wave of a 10-kHz frequency. When the burst wave of a 10-kHz

chlear damage is minimized if the dual method of gentamicin administration is used. The risk for hearing loss should, however, be explained to the patient. Gentamicin should be used particularly in patients who suffer a significant and severe hearing loss, and these patients should be warned about the possibility of additional hearing deficit. Although relief from tinnitus cannot be promised, the world literature indicates that most patients suffer less severe tinnitus after gentamicin treatment [17].

REFERENCES

1. Lange G: Die intratympanale Behandlung des Morbus Meniere mit ototoxischen Antibiotika. Langzeitbeobachtung von 55 Fällen. *Laryngol Rhinol* 56:409–414, 1977.
2. Lange G: Transtympanic treatment for Meniere's disease with Gentamicinsulfat. In Vosteen M, et al. (eds), *Meniere's Disease. International Symposium*, Düsseldorf. Stuttgart: Thieme, 1981;208–211.
3. Lange G: Die Indikation zur intratympanalen Gentamicin-Behandlung der Meniereschen Krankheit. *HNO* 29: 49–51, 1981.
4. Beck C, Schmidt C: Ten years of experience with intratympanally applied streptomycin (gentamycin) in the therapy of morbus Meniere. *Arch Otorhinolaryngol* 221: 149–152, 1978.
5. Ödkvist LM, Bergholtz LM, Lundgren A: Topical-gentamycin treatment for disabling Meniere's disease. *Acta Otolaryngol Suppl* (Stockh) 412:74–76, 1984.
6. Ödkvist LM: Middle ear ototoxic treatment for inner ear disease. *Acta Otolaryngol Suppl* (Stockh) 457:82–85, 1988.
7. Ödkvist LM, Magnusson M, Bergenius J, et al.: Quadruple Intratympanal Gentamicin Treatment for Meniere's Disease. In C Claussen (ed), *Diagnostic Procedures and Imaging Techniques Used in Neurootology. Proceedings of the NES*. vol 17. 1992;333–336.
8. Magnusson M, Padoan S: Delayed onset of ototoxic effects of gentamicin in treatment of Meniere's disease. *Acta Otolaryngol* (Stockh) 111:671–676, 1991.
9. Ödkvist LM, Ödkvist I: Physiotherapy in vertigo. *Acta Otolaryngol Suppl* (Stockh) 455:74–76, 1988.
10. Ödkvist LM, Noaksson L: Gentamicin Treatment for Disabling Meniere's Disease. In C Claussen (ed), *Proceedings of the NES*. XXI:37–41, 1995 Linköping. 1993.
11. Ödkvist LM, Magnusson M: Different Strategies in Gentamicin Treatment for Meniere's Disease. Presented at the Third International Symposium on Meniere's Disease, Rome, Italy, October 20–23, 1993.
12. Tran Ba Huy P, Bernard P, Schacht J: Kinetics of gentamicin uptake and release in the rat. *J Clin Invest* 77:1492–1500, 1986.
13. Tran Ba Huy P, Deffrennes D: Aminoglycoside binding sites in the inner ears of guinea pigs. *Antimicrob Agents Chemother* 467–472, 1988.
14. Lundquist PG, Wersäll J: The Ototoxic Effects of Gentamycin—an Electromicroscopical Study. In *Proceedings of the First International Symposium: Gentamycine*. Paris 1967;26–46.
15. Möller C, Ödkvist LM, Thell J, et al.: Vestibular and audiological functions in gentamicin treated Ménière's disease. *Am J Otol* 9:383–391, 1988.
16. Ödkvist LM, Ledin T: Recovery of equilibrium after intratympanal gentamicin in Meniere's disease. *Acta AWHO* 12:59–64, 1993.
17. Bergenius J, Ödkvist LM: Ototoxic Treatment of Meniere's Disease. In WM Halmagyi, R Baloh (eds), *Vestibular Disease*. New York: Oxford Publishers, 1996; 575–584.