

Ginkgo biloba (Rökan) Therapy in Tinnitus Patients and Measurable Interactions Between Tinnitus and Vestibular Disturbances

Dieter Schneider,¹ Lucia Schneider,¹ Abraham Shulman,²
Claus-Frenz Claussen,¹ Eberhardt Just,³ Christo Koltchev,¹
Michael Kersebaum,⁴ Ralf Dehler,⁵ Barbara Goldstein,² and Erika Claussen⁶

¹University Head Center, Ear, Nose, and Throat Department, Neurotology Unit, Würzburg, Germany; ²Martha Entenmann Tinnitus Research Center, Health Sciences Center at Brooklyn, State University of New York, Brooklyn, New York, USA; ³German Brügger Center, Murnau, Germany; ⁴German Army Hospital, Koblenz, Germany; ⁵Rehabilitation Clinic and German Brügger Center, St. Peter-Ording, Germany; and ⁶Bad Kissingen, Germany

Abstract: Tinnitus is one of the most important symptoms in neurotology after vertigo, nausea, and hearing loss. In most cases, the origin of the tinnitus remains inexplicable. Well-known, however, is that tinnitus may arise in any part of the hearing pathway (i.e., both within the cochlea receptor and in the temporal lobe and projections). Tinnitus also is associated frequently with vertigo, nausea and hearing loss. An age predominance exists, with tinnitus more common among those older than 40 years. From this starting point, a great demand exists today for new ideas and developments in the diagnosis and treatment of tinnitus.

Keywords: competitive kinesthetic therapy; *Ginkgo biloba*; tinnitus

In the course of the last few years, we have used the technology of brain mapping of electrical activity as measured during angular vestibular accelerations in the neurotology department at the University Head Center of Würzburg. With this modality, we have successfully measured (and analyzed, using computer-assisted drafting techniques) late vestibular evoked potentials (VestEP), obtained from electrodes located on the scalp during repeated accelerations of the affected patient. The scalp-referred brain electrical activity mapping (BEAM) images indicate characteristic changes in patients with tinnitus [1].

An anatomical plan in sagittal and coronal cerebral sections measured from the vertex toward the foramen magnum with a display of important neuroanatomical structures, controlled by the central nervous system (CNS), which regulates both hearing and equilibrium

control, thus demonstrates how closely spatioacoustic processors are interrelated. Further, telencephalic and diencephalic supervisory loops modulate the activity in this area. As currently understood, the read-only memory functions of the basal ganglia play an important role in establishing driving patterns for various neurosensory internal and external transitions. Therefore, a modern concept of tinnitology must consider that afferent hearing is composed primarily of three discrete—and equally important—information chains, which are linked to acoustic space control, acoustic modulations of individual and social emotions, and acoustic transfer of intellectual (i.e., verbal) data.

The first two functions share common pathways with other neurosensory functions and encompass the sense of interaction within the sensorineural framework. Preliminary results of the therapy using extract of *Ginkgo biloba* (EGB 761) seem to be very promising in tinnitus therapy.

METHOD

The equipment assembly used in this study includes a servocontrolled ServoMed AB Rotation Chair RS/6

Reprint requests: Dieter Schneider, MD, University Head Center, Neurotology Unit, 11 Josef-Schneider-St., D-97080, Würzburg, Germany. Phone: (49) 931 201 2208; Fax: (49) 931 201 2349; E-mail: d.schneider@hno.uni-wuerzburg.de.

(Servo Med AB, Stockholm-Vallingby, Sweden). The biosignals are transmitted to the main amplifier through a slip-ring assembly containing 17 slip rings, each fitted with twin sliding contacts. Digital setting and monitoring of angular velocity and acceleration are available. The stimulus profile, programmed by a specially constructed function generator, takes the form of a raised-declined cosine impulse with a duration of 1.0 seconds in each phase. The vestibular stimulus represents a sequence of 25 stepwise angular accelerations with an acceleration rate of 15 degrees/sec², a maximal peak angular velocity of 15 degrees/sec, and an inter-stimulus interval of 14 sec.

The rotating chair in operation is completely silent. Even so, individual hearing protectors (Bilsom Propp-o-Plast, Sweden) are applied to both ears of the patient to avoid any possible acoustic contribution to the rotationally evoked potentials. Patients are positioned on the chair with the head inclined forward by 30 degrees. To minimize eye movement-related artifacts, gaze fixation is controlled through a structured fixation target that rotates with the chair. The chair is housed in a partially lighted room, which permits the examination to be carried out either in total darkness or in an illuminated environment. Patients' eye movements are monitored with a special electrooculography channel. Using this method of gaze fixation clearly shows that a well-marked suppression of the rotatory evoked nystagmus has taken place.

An electrode cap is placed over the scalp according to the international 10–20 system. Altogether, 19 scalp-located electrodes are used to study scalp topography of the VestEP. The amplification and paper monitoring of the raw electroencephalographic (EEG) data are accomplished using a 17-channel Picker Schwarzer Encephaloscript ES 16000. The derivation type that is adopted is monopolar, with a common reference electrode fixed over both mastoid bones. Upward deflections indicate scalp negativity, and downward deflections indicate positivity. This montage and derivation configuration is chosen after numerous tests to determine orientation. The frequency band of the recorded spontaneous brain electrical activity is determined by a low-frequency cutoff at 0.1 Hz and a high-frequency cutoff at 35 Hz. A 50-Hz notch filter is applied. The responses are monitored online and subsequently are processed on a Schwarzer Brain Surveyor BS 2400, which supplies modalities for spatial and chronological analysis of both spontaneous and evoked brain electrical activity (e.g., BEAM) [2]. An interval of 1,000 msec after onset of the stepwise acceleration stimulus is used for analysis of the rotationally evoked brain electrical events. Peak-to-peak amplitudes and principal component latencies are measured and subsequently are computed

on a personal computer (Macintosh, Cupertino, CA) for their averaged values and standard deviations.

Our studies encompassed two different therapeutic modalities. In one study involving five patients (four women, one man), drug therapy for tinnitus was attempted using a standardized extract of *Ginkgo biloba* (EGB 761) [3]. Patients ranged in age from 46 to 63 years (mean, 51.8 ± 6.6 yr). The patients, all of whom suffered from tinnitus of the severe, disabling type, were treated by a daily infusion of 200 mg EGB 761 for 7 days and afterward with an oral application of 160 mg EGB 761 (two single doses daily) for an additional 7 days. VestEP investigations were performed before and after the drug's administration.

In the other study, a special competitive kinesthetic therapy was employed to attempt tinnitus control in 20 patients. The latter therapy is based on principles of physiotherapy as explained by Brügger [4]. The treatment involves analysis and, if necessary, correction of whole-body expressions and global movement programs of the patient. Just observed in some patients during therapy for orthopedic disturbances an alteration in the finding of tinnitus. Intrigued by this preliminary finding, the team at our neurootological department conducted electrophysiological investigations of this phenomenon [5], after which Just and Dehler further developed competitive kinesthetic therapy.

RESULTS

The VestEP pattern represents a wave complex of six negative-positive deflections within the interval of 65–800 msec after onset of the vestibular acceleration step. In this study, an analysis was performed on the basis of the main latency-amplitude properties of the VestEP, obtained from the C3 (left central) and C4 (right central) electrode derivations. Amplitude of the VestEP was measured in terms of the voltage of the III-IV component, as measured from peak to peak. At present, according to former studies of our working group [1,5,6], three primary main findings are determined in patients with tinnitus: (1) shortening of the latencies from the first to the fourth VestEP components, (2) increased amplitude of the III-IV peak-to-peak component, and (3) DC shift of all VestEP components toward the negative pole. These VestEP-modifications are particularly clear in cases of monolateral tinnitus, in which the comparison is made between the VestEP parameters obtained when the rotation is directed to the side of the affected (tinnitus) ear versus rotation toward the side of the nonaffected ear.

Whole vestibular potential toward negativity when rotating to the direction of the affected side is of particular interest. On brain-mapping display, this appears as

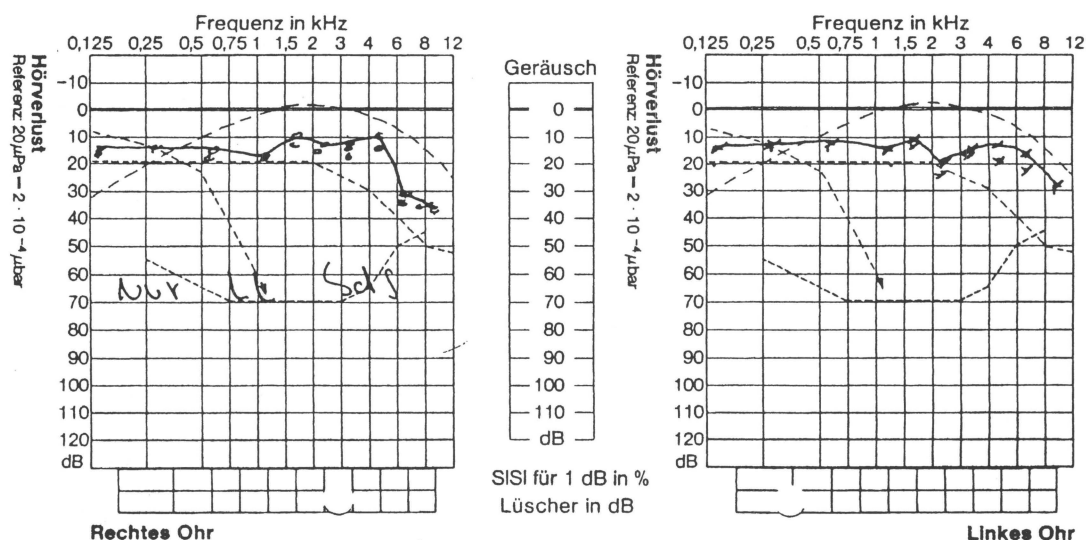


Figure 1. Pure-tone audiogram, Case 1.

an intense red map, when mapping, for example, the third VestEP component. This electrographic finding is seen in most tinnitus patients; however, it appears in two modified forms: bilateral DC shift of the VestEP maps toward negativity when rotated to the affected ear, and monolateral or localized DC shift toward negativity, independent of the direction of rotation. Because of the relatively low number of treated subjects, we did not attempt a statistical survey but instead present two typical cases from the *Ginkgo biloba* group and one typical case from the competitive kinesthetic therapy group.

Case Reports of *Ginkgo biloba* Group

Case 1

A 63-year-old female patient had suffered from left tinnitus of the severe, disabling type for 3 years. The pure-tone audiogram was normal (Fig. 1). The perceived auditory quality of the tinnitus was a loud murmur, and the noise could not be masked. She had no other neurootological complaints, such as vertigo or dizziness. She was suffering from hypertonus and bronchial asthma. The results of the VestEP tests are shown in

Table 1. Shortening of latencies III and IV could be seen during rotation to the left.

After 8 weeks of *Ginkgo biloba* therapy, a clear subjective improvement was seen in her condition in terms of reduced volume of tinnitus and generally improved perception of quality of life. Additionally, however, objective measurements clearly indicated a normalization of the VestEP findings. Rotation to the right and to the left demonstrated an intense prolongation of the earlier finding of shortened latencies and an adjustment of the latencies during clockwise and counterclockwise rotation (see Table 1).

Case 2

A 49-year-old female patient had suffered from left tinnitus of the severe, disabling type for 9 years. The pure-tone audiogram was normal (Fig. 2). The quality of the tinnitus was a constant noise of severe intensity, and it could not be masked. She voiced no other neurootological complaints and had no concomitant diseases. The results of the VestEP tests are shown in Table 2. Shortening of latency IV can be seen during rotation to the left (in relation to the rotation to the right).

Table 1. Latencies of the Vestibular Evoked Potentials Before and After *Ginkgo biloba* Therapy for Tinnitus: Case 1

Measurement	Clockwise Rotation		Counterclockwise Rotation	
	Wave III (msec)	Wave IV (msec)	Wave III (msec)	Wave IV (msec)
0	315	440	280	365
1 wk	365	540	330	535
8 wk	350	495	375	500
Normative values	336 ± 18	476 ± 16	336 ± 18	476 ± 16

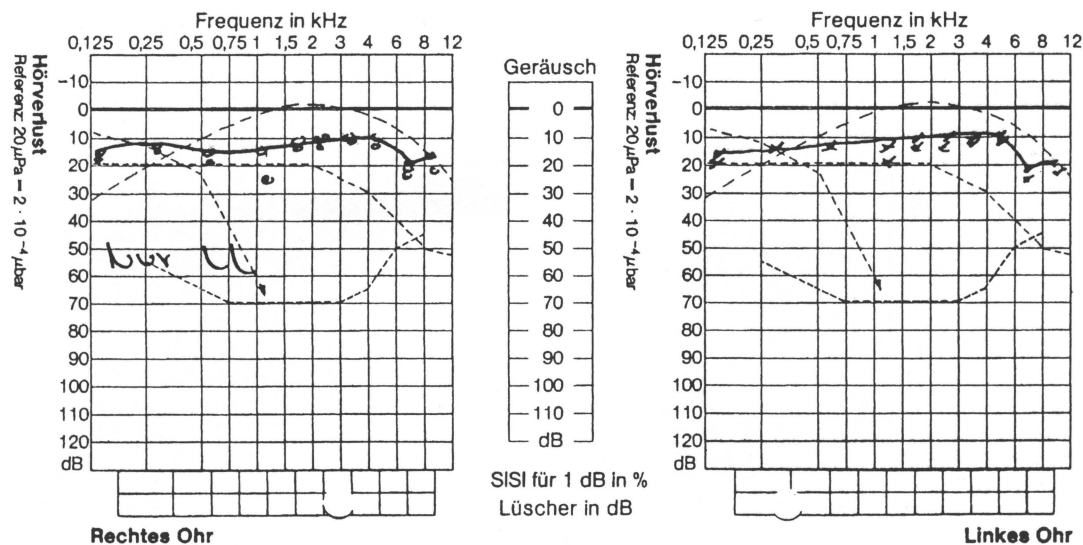


Figure 2. Pure-tone audiogram, Case 2.

After 8 weeks of *Ginkgo biloba* therapy, the patient exhibited a clear subjective improvement of the tinnitus condition. Rotation to the left produced an intense prolongation of the earlier finding of shortened latencies and an adjustment of the latencies during clockwise and counterclockwise rotation (Figs. 3, 4; see Table 2).

Case Report of Competitive Kinesthetic Therapy Group: Case 3

A 62-year-old male patient had suffered from bilateral tinnitus of the severe, disabling type for 8 years. Evident in the pure-tone audiogram was a moderate high-tone slope. The perceived auditory quality of the tinnitus was a loud murmur, and a side localization no longer was possible. The noise could not be masked. No other neurootological complaints, such as vertigo or dizziness, were reported. The results of the VestEP test are shown in Table 3. Shortening of the latencies (especially the late waves) can be seen during rotation to the right. In addition, the clinician should recognize a slight CD shift of the curve toward negativity. In left rotation, shortening of the latencies is less clear, but a clear shift

of the curve toward negativity is found, especially in the late waves (Fig. 5A).

After 4 weeks of competitive kinesthetic therapy, clear subjective improvement of the tinnitus was noted in terms of reduced volume and generally improved perception of quality of life. Additionally, however, objective measurements clearly indicated a normalization of the VestEP findings. Rotation to the right and to the left demonstrated an intense prolongation of the earlier finding of shortened latencies (see Table 3) and a disappearance of the negative DC shift (Fig. 5B).

DISCUSSION

Fundamentally, the character of the electrographical VestEP changes in the group of tinnitus patients is that of irritation. In our study, we have used the common mastoid as a referential electrode. Consequently, potential differences between the referential point (which is practically electrically silent) and each one of the scalp electrodes (which is electronegative with respect to the reference point) reflect the gradient of the relative cortical electronegativity during vestibular stimulation.

Table 2. Latencies of the Vestibular Evoked Potentials Before and After *Ginkgo biloba* Therapy for Tinnitus: Case 2

Measurement	Clockwise Rotation		Counterclockwise Rotation	
	Wave III (msec)	Wave IV (msec)	Wave III (msec)	Wave IV (msec)
0	320	580	300	490
1 wk	350	615	350	610
8 wk	355	535	370	575
Normative values	336 ± 18	476 ± 16	336 ± 18	476 ± 16

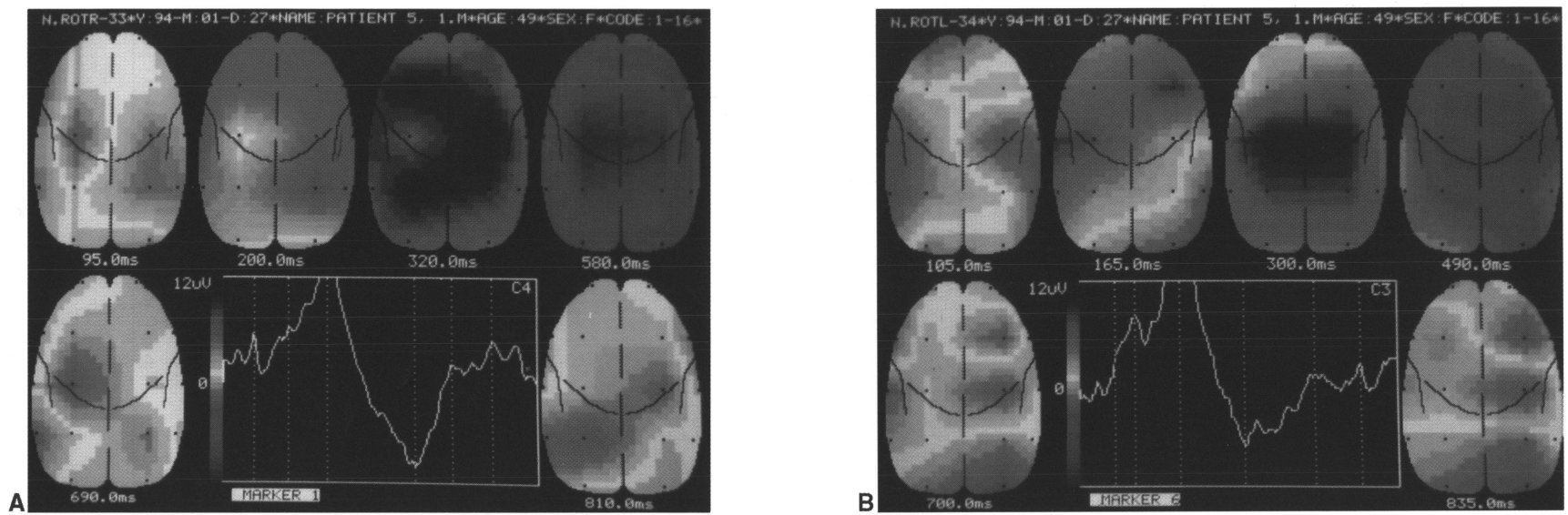


Figure 3. Vestibular evoked potentials on right rotation (A) before therapy and (B) after therapy in Case 2.

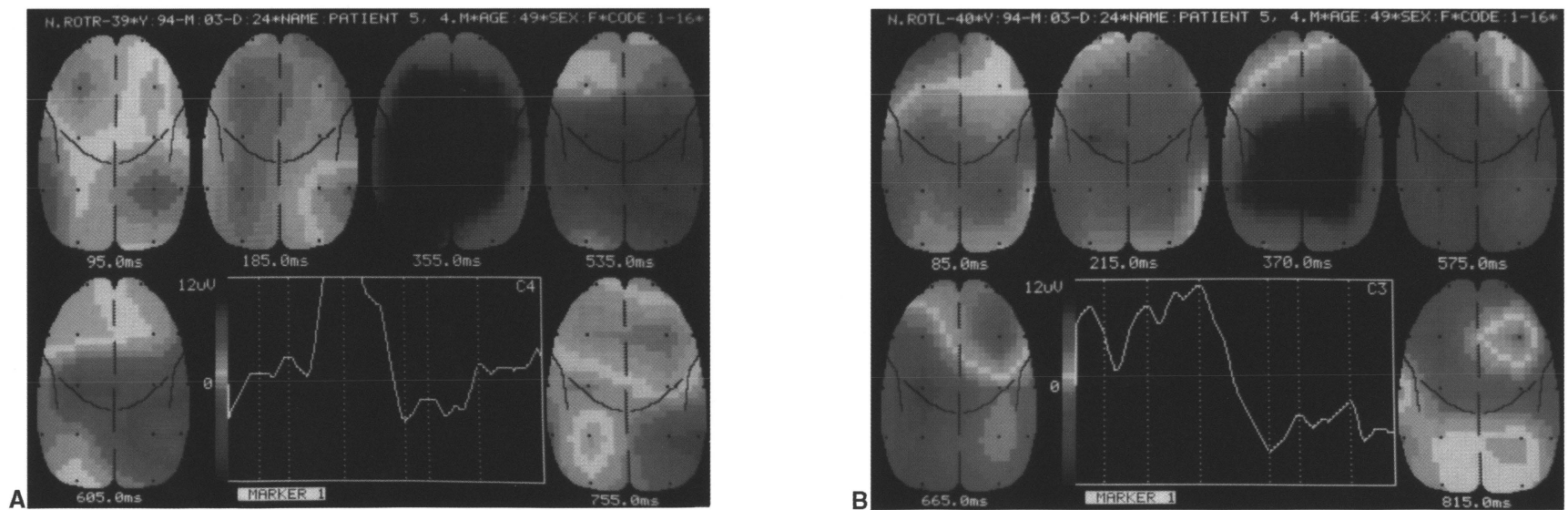


Figure 4. Vestibular evoked potentials on left rotation (A) before therapy and (B) after therapy in Case 2.

Table 3. Latencies of the Vestibular Evoked Potentials Before and After Competitive Kinesthetic Therapy for Tinnitus

Stimulus	Wave I (msec)	Wave II (msec)	Wave III (msec)	Wave IV (msec)	Wave V (msec)	Wave VI (msec)
Rotation to the right						
Pretherapy	80	135	315	435	530	680
Posttherapy	100	205	390	490	695	790
Rotation to the left						
Pretherapy	110	220	330	480	600	705
Posttherapy	125	215	365	490	625	795
Normative values (avg. \pm SD)	77 \pm 10	182 \pm 9	336 \pm 18	476 \pm 16	632 \pm 19	802 \pm 19

Electronegativity is a fundamental neurophysiological category. If an afferent influx of impulses occurs in vertically oriented cortical neurons at a high frequency for a longer period, wavelike excitatory postsynaptic potentials will be generated at the superficial dendritic arborization. This produces widespread depolarization

of the cortical neuronal elements. This prolonged depolarization of the superficial structures caused by sensory afferentation manifests itself by a negative shift in the EEG, in particular the negative DC-EEG potential shift [7]. However, this high level of spontaneous activity could be caused either by hyperactive neurons or by

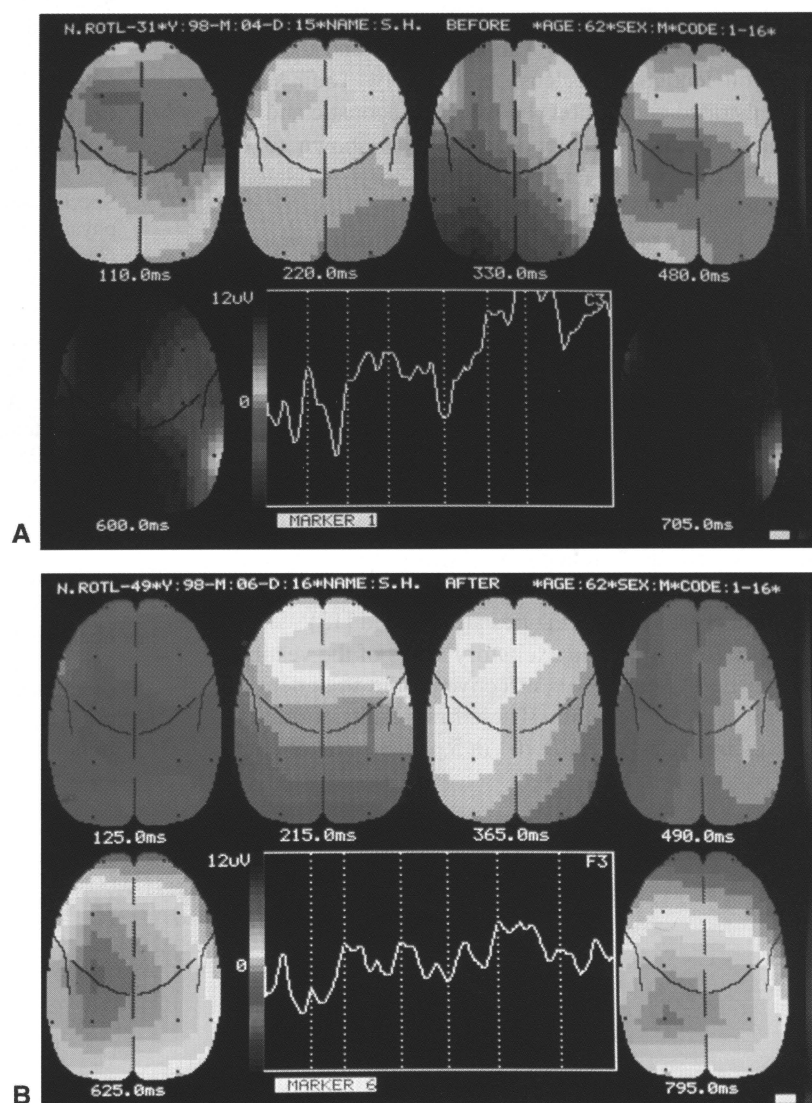


Figure 5. Vestibular evoked potentials on left rotation (A) before therapy and (B) after therapy in Case 3.

hypersensitive (i.e., low-threshold) neural structures. Both hyperactivity and hypersensitivity can be caused by loss of inhibition [8]. Shulman [9] postulated a "final common pathway for tinnitus" in all patients with tinnitus of the severe, disabling type in the medial temporal lobe system. Perfusion asymmetries in the hippocampus-amygdala complex were demonstrated by single-photon emission computed tomography (SPECT). He stated the presence of a "paradoxical memory" for an aberrant auditory signal within these brain structures. In a further complex process, transformation of the perceived sensory phenomena into the affective component of tinnitus (e.g., moods, emotions, disturbed sleep, stress, anxiety, general behavior) is performed in these structures of the limbic system.

Perfusion asymmetries in tinnitus patients are demonstrated in other work by Shulman et al. [10] and Shulman and Goldstein [11] using SPECT. Using positron emission tomography in patients with unilateral tinnitus, Lockwood et al. [12] recorded increased activity in the contralateral hippocampus and the contralateral lenticular nucleus, respectively. Their study demonstrated connections between the acoustic and the limbic systems. The hippocampus was shown to be strongly involved in learning and memory. A bilateral destruction of the hippocampus leads to a loss of the ability to learn new things. In addition, affected patients are not able to remember things they had learned a short time before the destruction of the hippocampus. The long-term memory remains relatively unchanged.

Connections between the limbic and acoustic systems have been subject to discussion for a long time. Acoustic hallucinations in a temporal lobe epilepsy occur in the frame of an "epileptic aura." Animal trials provided evidence that glutaminergic pathways play an important role in this context. If inhibitory gamma-aminobutyric acid-related interneurons are blocked, which normally inhibit the effect of the excitatory glutaminergic system, seizures are induced [13].

EGB 761 influenced excitatory states of the vestibuloacoustic system and is effective in the treatment of central excitatory tinnitus. These first results of tinnitus therapy by means of EGB 761 in 5 patients and of com-

petitive kinesthetic therapy in 20 patients are very promising. It is postulated that these methods will open a new direction in the treatment of tinnitus.

REFERENCES

1. Claussen CF, Schneider D, Koltchev CH. On the functional state of central vestibular structures in monaural symptomatic tinnitus patients. *Int Tinnitus J* 1:5–12, 1995.
2. Duffy FH, Iyer VG, Surwillo WW. *Clinical Electroencephalography and Topographic Brain Mapping: Technology and Practice*. Berlin: Springer-Verlag; 1989.
3. Meyer B. Randomisierte placebokontrollierte doppelblinde Multicenterstudie zur Wirksamkeit von Rökän bei Tinnitus. In C. Diehm, D. Müller (eds), *Rökän, Ginkgo biloba EGB 761, Band 2, Klinik*. Berlin: Springer; 1992:244–248.
4. Brügger A. *Erkrankungen des Bewegungsapparates und seines Nervensystems*. Stuttgart: G Fischer, 1976.
5. Schneider D, Koltchev Ch, Constantinescu L, Claussen CF. Vestibular evoked potentials (VestEP) and brain electrical activity mapping—a test of vestibular function—a review (1990–1996). *Int Tinnitus J* 2(1):27–44, 1996.
6. Constantinescu L, Schneider D, Claussen CF. Vestibular evoked potentials in two patients with bilateral vestibular loss. *Int Tinnitus J* 1996; 2(1):45–58, 1996.
7. Speckmann E-J, Elger CE. Introduction to the Neurophysiological Basis of the EEG and DC Potentials. In E. Niedermeyer, F. Lopes da Silva (eds), *Electroencephalography: Basic Principles, Clinical Applications and Related Fields*. Munich: Urban & Schwarzenberg, 1987:1–14.
8. Eggermont JJ. Tinnitus: Some Thoughts about Its Origin. Ashford, Kent: Headley Brothers/Invicta Press, 1984.
9. Shulman A. A final common pathway for tinnitus—the medial temporal lobe system. *Int Tinnitus J* 1(2):115–126, 1995.
10. Shulman A, Strashun AM, Afriyie M. SPECT imaging of brain and tinnitus—neurotologic/neurologic implications. *Int Tinnitus J* 1(1):13–29, 1995.
11. Shulman A, Goldstein B. SPECT of brain and vertigo—a case report. *Int Tinnitus J* 2(1):59–65, 1996.
12. Lockwood AH, Salvi RJ et al. The functional neuroanatomy of tinnitus: Evidence for limbic system links and neural plasticity. *Neurology* 50(1):114–120, 1998.
13. Zilles K, Rehkämper G. *Funktionelle Neuroanatomie*. Berlin: Springer, 1993:334–342.