

Morphological and Dimensional Measurements' Study of Human Mandibular Canal Using CBCT Technique

Mohammed Shakir Shnawa^{1*},
Mohammad Ahmad Abdalla²,
Saad Ahmed Mohammed²

ABSTRACT

Introduction: The Mandibular Canal (MC) is the major neurovascular canal in the lower jaw, it runs from the mandibular foramen, which present in the medial surface of the ramus of the mandible, to the Mental Foramen (MF). A total of 82 patients (164 hemi-mandibular CBCT scans) were randomly selected from different specialized dental centers in Iraq. These cases were collected during the extended period from September 2023 to March 2024. The patients (42 males and 40 females) were divided into four age groups.

Results: Of this study revealed that for the course of the MC, the progressive descent type was the most common, appearing in 121 (73.78%) scans, followed by the catenary-like type in 31 (18.90%) scans, then the linear type in 12 (7.32%) scans. The MC's length on the right side ranged between (54.1–78.4) mm with mean value being (67.039 ± 4.611) mm, while on the left side it ranged between (53–75.6) mm with mean value being (66.833 ± 4.475) mm. It was found that the mean VD of the MC on both sides reached its highest value at the SM area and then gradually decreased until the SP area. Individuals of male gender had a higher mean HD of the MC than female individuals, a statistically significant finding at all the measured points. The mean distance between AC and the upper margin of the MC was significantly higher in male patients than female patients at all the measured points. The mean distance between IBM and the lower margin of the MC was greater in male patients than their female counterparts (7.503 mm versus 7.109 mm), but was not statistically significant. The position of the MC was found to be near the LCP in the SM and FM areas, while it was close to the BCP in the SP area.

Conclusion: The progressive descent type was the most frequent type of the MC course, followed by the catenary-like type. The length of the MC was significantly greater in males than females. Age, side, and sex had no significant influence on the mean VD of the MC. While the mean HD of the MC was significantly greater in males than females. The mean MC-BCP and MC-AC distances presented marked gender differences, with greater values found in males than females. While the mean MC-LCP and MC-IBM distances were not affected by sex.

Keywords: Mandibular canal, Neurovascular canal, Mental foramen, Hemi-mandibular, Mandibular foramen.

¹Department of Human Anatomy, College of Dentistry, Kufa University, Najaf, Iraq

²Department of Human Anatomy, College of Medicine, Tikrit University, Tikrit, Iraq

***Send correspondence to**

Mohammed Shakir Shnawa

Department of Human Anatomy, College of Dentistry, Kufa University, Najaf, Iraq, E-mail: ms230032pme@st.tu.edu.iq

INTRODUCTION

The Mandibular Canal (MC) is the major neurovascular canal in the lower jaw, it runs from the mandibular foramen, which present in the medial surface of the ramus of the mandible. It travels downward and forward through the ramus, then continues forward horizontally through the body to reach the Mental Foramen (MF)¹.

The MC is typically a singular entity, found on both sides of the lower jaw. It contains the Inferior Alveolar Nerve (IAN) and vascular bundle, comprising artery and vein². The largest branch of the mandibular nerve's posterior division is the IAN. This nerve enters the mandible through the mandibular foramen, providing innervation to the chin, lower lip, mandibular teeth, and buccal gingivae of the anterior teeth. It passes through the MC until it splits into its major terminal branches, the Mental Nerve (MN) and the incisive nerve, prior to exiting the MF^{3,4}.

The Cone Beam Computed Tomography (CBCT) is a relatively new imaging technique used in dentistry to acquire three-dimensional images of the oral and maxillofacial areas. The resulting images are of high resolution and devoid of distortion. In comparison, CBCT scans require remarkably fewer radiation doses than traditional computed tomography scans. This degree of precision aids in analyzing the anatomy and discovering any problems⁵.

MATERIALS & METHODS

This study was approved by the Medical Ethics Committee of Tikrit University College of Medicine (Code IQ.TUCOM.REC.3/7/272). Ethical approval statements were acquired for all participated individuals, depending upon Helsinki Declaration of World Medical Association; with its last revision at Edinburgh in 2000.

A total of 82 patients (164 hemi-mandibular CBCT scans) were randomly selected from different specialized dental centers in Iraq. These cases were collected during the extended period from September 2023 to March 2024. The patients (42 males and 40 females) were divided into four age groups: group 1: (20-30) years old, that included 23 patients (12 males and 11 females), group 2: (31-40) years old, that included 22 patients (10 males and 12 females), group 3: (41-50) years old, that included 20 patients (11 males and 9 females), and group 4: over 50 years old, that included 17 patients (9 males and 8 females).

The current study included CBCT scans taken for different diagnostic purposes, images of adequate diagnostic quality, presence at least two of the following three teeth: Second Premolar (SP), First Molar (FM), and Second Molar (SM), and age equal to or older than 20 years old. The CBCT scans were excluded if there is any pathology, supernumerary teeth, impacted teeth, or fracture in the region of interest, poor quality with processing or exposure error and artifacts.

The following parameters were assessed on CBCT:

1- The topographical course of the MC according to the Worthington classification (6): the MC course was traced, highlighted, and marked in the panoramic reconstructed images. Then, the pattern of the MC course was categorized according to the Worthington study.

2- The length of the MC: after locating a midpoint in the mandibular foramen and MF regions, the length of the MC was measured in the panoramic view by following the line that passed between the two points in the midline between the upper and lower cortication of the MC (**Figure 1**).

3- The diameters of the MC: by using the software's measurement tool in the coronal plane, the inner maximum Vertical Diameter (VD) and Horizontal Diameter (HD) of the MC were measured at three reference points: A- tip of SP root, B- tip of FM distal root, and C- tip of SM distal root.

4- The location of the MC: the distance from the exterior border of the MC to the Buccal Cortical Plate (BCP), Lingual Cortical Plate (LCP), Alveolar Crest (AC), and Inferior Border of Mandible (IBM) were measured at three reference points; A- tip of SP root, B- tip of FM distal root, and C- tip of SM distal root (**Figure 2**).

Data were described, analyzed, and presented using the statistical software for social science (SPSS version -22, Chicago, Illinois, USA). The mean, standard deviation, and statistical parametric tests were determined. Tables and graphs were created, and statistical significance was identified using the independent samples T-test, chi square test, and ANOVA test. A P-value less than 0.05 was considered statistically significant

RESULTS

The Topographical Course of the MC:

The progressive descent type of the MC was the most common type, appearing in 121 (73.78%) scans, followed by the catenary-like type in 31 (18.90%) scans, then the linear type in 12 (7.32%) scans. There was a statistically non-significant difference between the right and left sides (**Table 1**), the four age groups, and between gender in measurements.

The Length of the MC:

The MC's length on the right side ranged between (54.1-78.4) mm. On the left side, the length ranged between (53-75.6) mm (**Table 2**). A statistically significant finding, that males had MCs that were longer than those of females (**Figure 3**). Also, there was significant difference between age in measurements, the length was greater in group 1 and group 2 but decreased gradually in old age groups.

The Diameters of the MC:

The mean VD of the MC on both sides reached its highest value at the SM area and then gradually decreased until the SP area (**Table 3**). There was no significant difference between sex, side, or age groups.

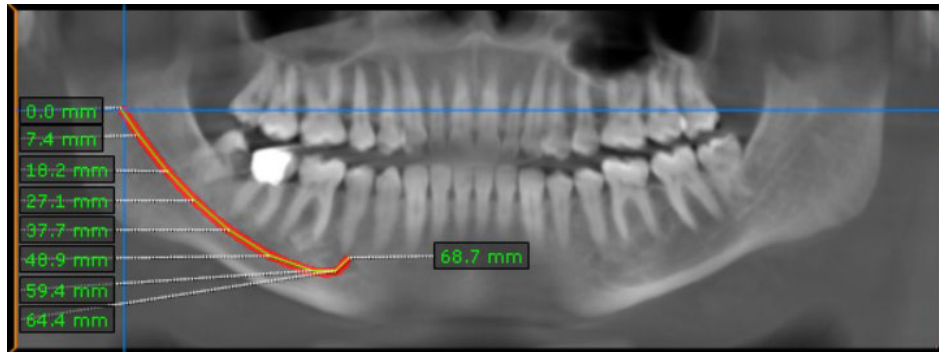


Figure 1: The length of the MC is 68.7 mm.

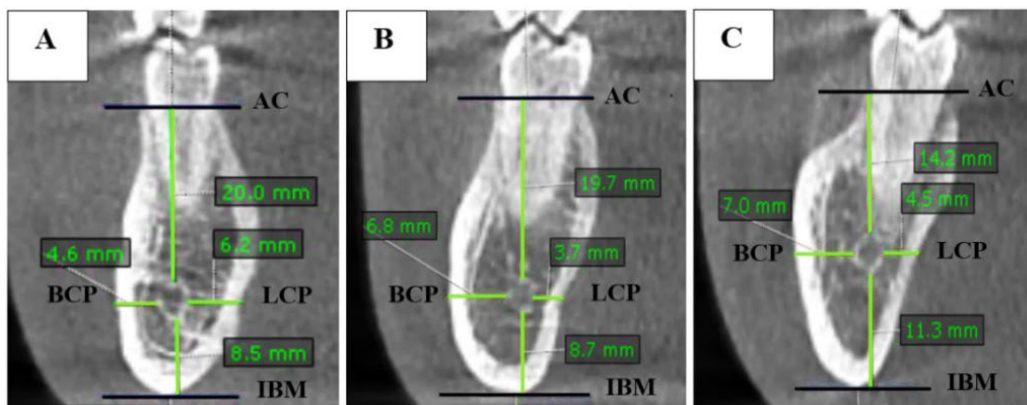


Figure 2: The distance measured from the MC's exterior border to the BCP, LCP, AC, and IBM at three reference points: A- tip of SP root, B- tip of FM distal root, and C- tip of SM distal root.

Table 1: Comparison of the topographical course of the MC between right and left sides.

Shape	Right		Left		Chi square	Total	
	N.	%	N.	%		N.	%
Progressive descending	59	48.76	62	51.24	0.798	121	73.78
Catenary	16	51.61	15	48.39		31	18.9
Linear	7	58.33	5	41.67		12	7.32

Table 2: Comparison of the MC length between right and left sides.

N	Right				N	Left				T test	P value
	Minimum	Maximum	Mean	±SD		Minimum	Maximum	Mean	±SD		
82	54.1	78.4	67.039	4.611	82	53	75.6	66.833	4.475	0.29	0.772

Individuals of male gender had a higher mean HD of the MC than female individuals. A statistically significant finding at all the measured points (**Table 4**). There was no significant difference between side or age groups.

The Location of the MC:

The mean distance between AC and the upper margin of the MC was significantly higher in male patients than female patients at all the measured points (**Table 5**). Also, it was greater in the first age groups (group 1 and 2), but decreased gradually in old age groups, and this finding was statistically significant at SP and FM roots tips (**Figure 4**). The difference in this parameter was not significant between side groups.

The mean distance between IBM and the lower margin

of the MC was greater in male patients than their female counterparts (7.503 mm versus 7.109 mm), but was not statistically significant. There was no significant difference between side or age groups.

The position of the MC was found to be near the LCP in the SM and FM areas, while it was close to the BCP in the SP area. The mean distance between BCP and the outer margin of the MC was higher in males than their female counterparts, this finding was significant statistically at all the measured points (**Table 6**). The mean distance between LCP and the outer margin of the MC was greater in male patients than female patients but not statistically significant. There was no significant difference in these parameters between side and age groups.

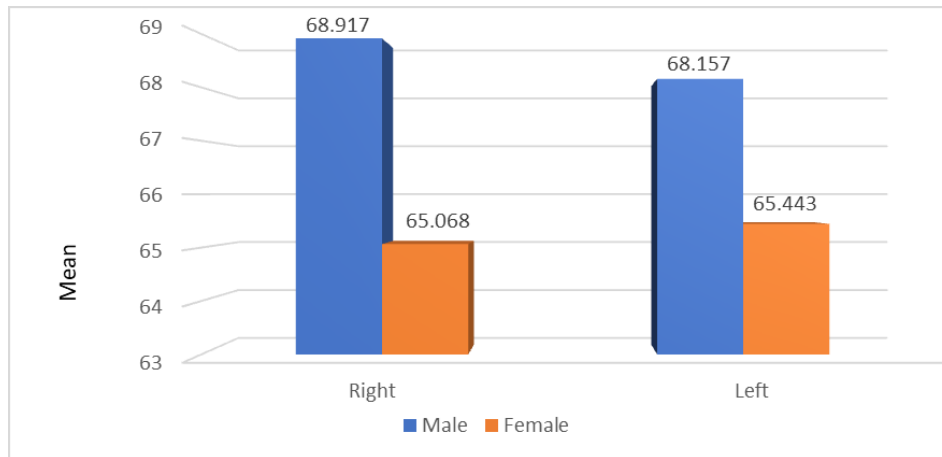


Figure 3: A clustered bar chart shows a comparison in the mean MC length between males and females.

Table 3: Comparison of the VD of the MC between right and left sides.

		Right					Left					T test	P value
	N	Minimum	Maximum	Mean	±SD	N	Minimum	Maximum	Mean	±SD			
VD SP	79	1.6	3.9	2.414	0.483	79	1.3	3.6	2.508	0.493	0.078	0.938	
VD FM	61	1.7	3.7	2.507	0.485	62	1.6	4.2	2.597	0.496	1.02	0.31	
VD SM	67	1.3	4.4	2.657	0.557	62	1.4	3.8	2.711	0.499	0.585	0.56	

Table 4: Comparison between males and females regarding the HD of the MC.

Side		Male						Female						T test	P value
		N	Minimum	Maximum	Mean	±SD	N	Minimum	Maximum	Mean	±SD				
Right	HD SP	40	1.3	4.5	2.793	0.67	39	1.3	3.5	2.241	0.422	4.364	0		
	HD FM	32	1.7	3.2	2.375	0.413	29	1.4	3	2.041	0.409	3.165	0.002		
	HD SM	32	1.8	3.5	2.669	0.469	29	1.5	3.3	2.328	0.445	2.907	0.005		
Left	HD SP	40	1.9	4.8	2.795	0.624	39	1.4	3.4	2.321	0.405	3.997	0		
	HD FM	32	1.3	3.2	2.403	0.511	29	1.3	3.4	2.1	0.5	2.358	0.022		
	HD SM	35	1.6	3.3	2.648	0.585	32	1.2	3.9	2.104	0.448	4.252	0		

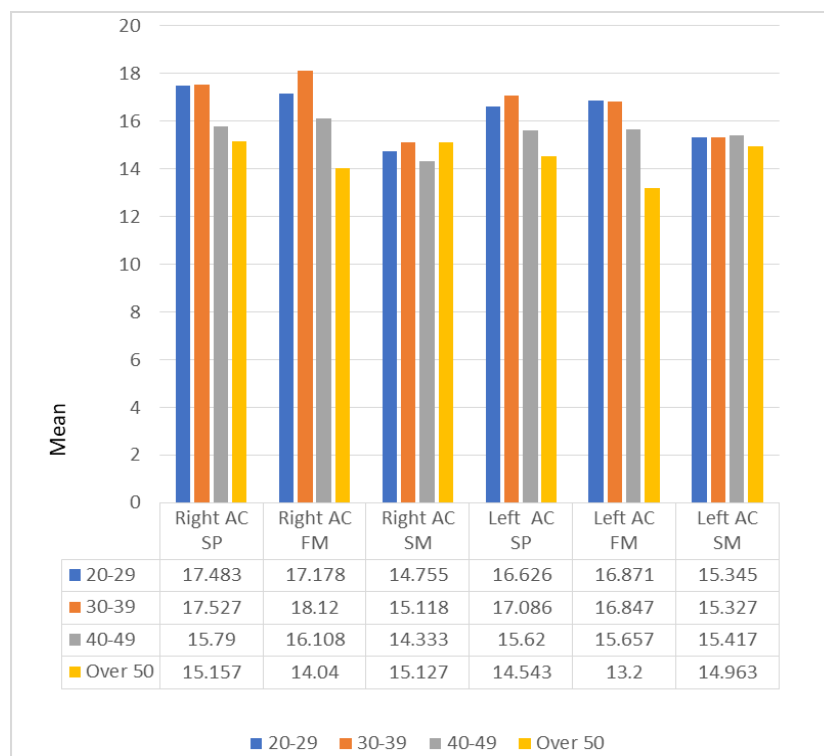


Figure 4: A clustered bar chart shows a comparison in the mean MC-AC distance between age groups.

Table 5: Comparison of the MC-AC distance between males and females.

Sides		Male					Female					T test	P value
		N	Minimum	Maximum	Mean	±SD	N	Minimum	Maximum	Mean	±SD		
Right	AC SP	40	8.2	20.8	17.348	2.693	39	11.6	20.1	15.944	1.752	2.739	0.008
	AC FM	32	12.8	23	17.853	2.364	29	10.3	21	15.359	2.354	4.125	0
	AC SM	35	10.1	20.9	15.8	2.204	32	11.5	17.8	14.297	1.711	1.861	0.005
Left	AC SP	40	8.8	20.5	16.94	2.313	39	9.5	19.1	15.454	2.049	3.02	0.003
	AC FM	32	9.2	19.5	16.434	2.411	30	9.4	20.3	15.217	2.359	2.008	0.049
	AC SM	35	11.3	19.3	16.784	2.333	31	11.8	19.3	14.291	2.246	4.127	0

Table 6: Comparison of the MC-BCP distance between males and females.

Sides		Male					Female					T test	P value
		N	Minimum	Maximum	Mean	±SD	N	Minimum	Maximum	Mean	±SD		
Right	BCP SP	40	1.3	7.1	2.968	1.091	39	1.2	4.6	2.413	0.611	2.779	0.007
	BCP FM	32	3.1	8.3	5.106	1.252	29	2.8	6.5	4.131	1.083	3.238	0.002
	BCP SM	35	3.6	9.6	5.537	1.41	32	3.1	6.2	4.659	0.765	3.125	0.003
Left	BCP SP	40	1.8	6.2	2.912	0.976	39	1.2	4	2.536	0.504	2.147	0.035
	BCP FM	32	3	8.4	5.277	1.224	30	2.8	7.3	4.303	1.036	3.221	0.002
	BCP SM	31	3.5	9.3	5.568	1.314	31	3.5	7.9	4.932	1.073	2.085	0.041

DISCUSSION

The progressive descent type of MC was the most common, followed by the catenary-like type, a finding similar to Shrestha P et al⁷. There was no correlation between the MC's course type and sex, this agrees with Okiriamu A et al⁸.

The mean value on right side was 67.039 mm, while on the left side the mean value was 66.833 mm. The present data was higher than the data presented by Komal A et al⁹ who investigated the Indian population and lower than Muñoz G et al¹⁰ who investigated the Brazilian population. The differences observed with previous researches may be explained by the population studied and the technique of analysis used for the measuring the length of the MC.

In this study, the difference in the VD and HD between the right and left sides was not significant. This agrees with Mirhosei F et al¹¹, and disagrees with Hamid M et al¹². The mean HD of the MC was significantly higher in males than females (2.613 mm versus 2.189 mm). There was no significant difference between age groups. This agrees with Safi Y et al¹³ and Chrcanovic B et al¹⁴, and disagrees with Abdalla MA¹⁵. The variation from the present study may be explained by differences in the sizes of bodies among the populations thought to be a considerable factor, as well as bone pathologies that can alter the diameters of the canal.

The position of the MC was found to be near the LCP in the SM and FM areas, while it was close to the BCP in the SP area. The mean distance between BCP and the outer margin of the MC was greater in males than their female counterparts, this finding was significant statistically at all the measured points. The mean distance between LCP and the outer margin of the MC was greater in male patients than female patients but not significant. In contrast, Kalabalik F et al¹⁶ found that the mean MC-BCP distance had no significant correlation with gender, and the mean MC-LCP

distance was significantly greater in males than females. While Sharaan ME et al¹⁷ and Mohammad SA et al¹⁸ found that found that the mean MC-BCP and MC-LCP distances showed no significant relation with sex.

The present study revealed that the mean distance from IBM to the lower margin of the MC in males was higher than females but not significant. The mean distance from AC to the upper margin of the MC was significantly greater in males than females. This agrees with Padayachee S et al¹⁹ who found that AC to MC distance was significantly greater in males than females, and disagrees with Alrahaimi SF et al²⁰ who found that there was no statistically significant difference between males and females regarding AC to MC distance. In other study by Cartes G et al²¹ found that the mean MC-IBM distance was higher in male patients than female patients, this was determined to be significant only near the tip of the SP root. The variance from the current study may be due to differences in geographic areas and certain ethnic population.

CONCLUSION

The progressive descent type of MC was the most frequent, followed by the catenary-like type. The length of the MC in the present Iraqi sample was significantly greater in males than females. Age, side, and sex had no significant influence on the VD of the MC, while the mean HD of the MC was significantly greater in males than females (2.613 mm versus 2.189 mm).

The position of the MC was found to be near the LCP in the SM and FM areas, while it was close to the BCP in the SP area. The mean MC-BCP and MC-AC distances presented marked gender differences, with greater values found in males than females. While the mean MC-LCP and MC-IBM distances were not affected by sex. All parameters were not affected by side.

REFERENCES

1. El-Bahnasy SS, Youakim M, Shamel M, El Sheikh H. Mandibular Canal Location and Cortical Bone Thickness in Males and Females of Different Age Groups: A Cone-beam Computed Tomography Study. *Open Access Maced J Med Sci.* 2021;9(A):1117-22.
2. Valenzuela-Fuenzalida JJ, Cariseo C, Gold M, Díaz D, Orellana M, Iwanaga J. Anatomical variations of the mandibular canal and their clinical implications in dental practice: a literature review. *Surg Radiol Anat.* 2021;43:1259-72.
3. Patel N, Langaliya A, Kanodia S, Kumbhar A, Buch A, Shah A, et al. Mental nerve paraesthesia: a report of two cases associated with endodontic etiology. *Case Rep Dent.* 2021;2021(1):1747519.
4. Al-Nasiri NA, Mohammed SA, Abdalla MA. Study of geometrical measurements of an adult human canine tooth in both jaws in Salah Al-Din governorate. *J Res Med Dent Sci.* 2022;10(3):207-12.
5. Weiss R, Read-Fuller A. Cone beam computed tomography in oral and maxillofacial surgery: an evidence-based review. *J Dent.* 2019;7(2):52.
6. Worthington P. Injury to the inferior alveolar nerve during implant placement: a formula for protection of the patient and clinician. *JOMI.* 2004;19(5).
7. Shrestha P, Humagain M, Koju S, Maskey S. Radiographic assessment of mandibular canal in Nepalese population: a study based on cone beam computed tomography images. *J Chitwan Med Coll.* 2019;9(4):52-6.
8. Okiriamu A, Butt F, Opondo F, Onyango F. Morphology and Variant Anatomy of the Mandibular Canal in a Kenyan Population: A Cone-Beam Computed Tomography Study. *CMTR.* 2023;8:27528464231182775.
9. Komal A, Bedi RS, Wadhvani P, Aurora JK, Chauhan H. Study of normal anatomy of mandibular canal and its variations in Indian population using CBCT. *J Maxillofac Surg.* 2020;19:98-105.
10. del Canal Mandibular RA, Muñoz G, Dias F, Weber B, Betancourt P. Anatomic relationships of mandibular canal. A cone beam CT study. *Int J Morphol.* 2017;35(4):1243-8.
11. Mirhoseini F, Baghestani M, Khajezade MH, Derafshi A. location and dimension of mandibular canal on cone beam computed tomography: A cross sectional study. *Jorjani Biomed J.* 2019;7(4):40-8.
12. Hamid MM, Suliman AM. Diameter of the inferior alveolar canal-a comparative CT and macroscopic study of sudanese cadaveric mandibles. *J Evol Med Dent Sci.* 2021;10:342-6.
13. Safi Y, Amid R, Kadkhodazadeh M, Rezaei S, Kazeminia M. Anatomical Variations of the Mandibular Canal and Mental Foramen in Full Edentulous Iranian Subpopulation: A Cone-Beam Computed Tomographic Study. *SEMJ.* 2022;23(11).
14. Chrcanovic BR, de Carvalho Machado V, Gjølvd B. A morphometric analysis of the mandibular canal by cone beam computed tomography and its relevance to the sagittal split ramus osteotomy. *J Oral Maxillofac Surg.* 2016;20:183-90.
15. Abdalla MA. Anatomical study for mental foramen in Iraqi adults. *Tikrit Med J.* 2013;19(1):185-90.
16. Kalabalik F, Aytuğar E. Localization of the mandibular canal in a Turkish population: A retrospective cone-beam computed tomography study. *J Oral Maxillofac Surg.* 2019;10(2):152-9.
17. Sharaan ME, Abdulla AY, Ragab MH. Assessment of the relationship of the distance between mandibular first and second molars with the inferior alveolar canal and cortical bone plate in an Egyptian subpopulation: a CBCT study. *Braz Oral Res.* 2022;36:24-8.
18. Mohammad SA, Abd-alla MA, Mahdi AJ. Mandibular notch configuration in Iraqi adults. *J Dent Sci.* 2012;2(2):175-8.
19. Padayachee S, Holmes H, Parker ME. Determining an average distance from the external mandibular cortex to the inferior alveolar canal using cone beam computed tomography (CBCT) imaging: an aid to harvesting mandibular ramus autogenous grafts. *S Afr Dent J* 2016;71(9):390-4.
20. Alrahaimi SF, Venkatesh E. Localization of mandibular canal and assessment of the remaining alveolar bone in posterior segment of the mandible with single missing tooth using cone-beam computed tomography: a cross sectional comparative study. *J Korean Assoc Oral Maxillofac Surg.* 2017;43(2):100-5.
21. Cartes G, Garay I, Deana NF, Navarro P, Alves N. Mandibular Canal Course and the Position of the Mental Foramen by Panoramic X-Ray in Chilean Individuals. *Biomed Res Int.* 2018;22(1):113-9.