

Spontaneous Resolution, After Superselective Angiography, of Pulsatile Tinnitus Resulting from Dural Arteriovenous Fistula

Ahmad A. Orabi and Richard Ramsden

Department of Otolaryngology, Head and Neck Surgery, Manchester Royal Infirmary, Manchester, UK

Abstract: We present an unusual case of subjective right-sided pulsatile tinnitus that resolved spontaneously within a few weeks after diagnostic superselective angiography. The possibility of dural arteriovenous fistula should be kept in mind even in subjective tinnitus. Conventional angiography may be the only modality that shows the abnormality.

Key Words: angiography; dural arteriovenous fistula; pulsatile tinnitus

Pulsatile tinnitus (coinciding with the patient's heartbeat) is an uncommon otological symptom and can often be a diagnostic problem. It raises the possibility of vascular abnormality [1]. In many instances, pulsatile tinnitus can be heard by an examining physician (objective tinnitus). Accurate diagnosis is essential, as many of its causes are treatable, whereas failure to identify the cause correctly can be catastrophic to some patients. We report an unusual case of *subjective* pulsatile tinnitus caused by arteriovenous fistula (AVF).

CASE REPORT

A 58-year-old woman presented with sudden onset of right-sided pulsatile tinnitus of 2 months' duration. It coincided with her pulse rate and increased when she exercised. It became more intrusive, and the patient became very distressed and anxious, so much so that she decided to retire from her work as a medical secretary. The rest of her otological history and medical history were unremarkable. Otological, otoneurological, and neurological examinations revealed no abnormality. Auscultation over the neck, skull, and mastoid process failed to reveal a bruit. Pure-tone audiometry and middle-ear

pressures were normal. Magnetic resonance imaging (MRI) of her brain and skull base was normal.

The patient was then referred to the tinnitus counseling clinic, where she drew attention to a raised vessel behind her right ear, something she first noticed at the time her symptoms started. A prominent pulsating could be felt in the artery in the postauricular region. Occlusion of the ipsilateral carotid in the neck immediately abolished her tinnitus.

We performed superselective angiography. Injections were made into the right internal and external carotid arteries and into the left common carotid and both vertebral arteries. An AVF malformation was demonstrated to involve mainly the right sigmoid and transverse sinuses, with multiple arterial feeders from the right external carotid artery, mainly the occipital artery (Fig. 1). Minor contributions stemmed both from the ascending pharyngeal and meningeal arteries and from tentorial branches of the internal carotid. No arterial supply came from the left side. Venous drainage was antegrade, with no evidence of reflux into the cortical veins. We made a diagnosis of a type 1 dural AVF with benign angiographic appearances.

We discussed various options, including exploration of the neck with ligation of the occipital artery. Because of the patient's reluctance to undergo surgery and because the risk of a neurological event was considered to be extremely low, we decided on conservative management and followed up the patient in the clinic. The tinnitus gradually diminished and, 2 months later, completely resolved. The previously palpable artery behind the ear disappeared, and we discharged the patient.

Reprint requests: Dr. Ahmad A. Orabi, Home 6, Victoria Court, Whinney Heys Road, Blackpool, United Kingdom, FY3 8NR. Phone: +441253-655770; E-mail: aorabi@hotmail.com

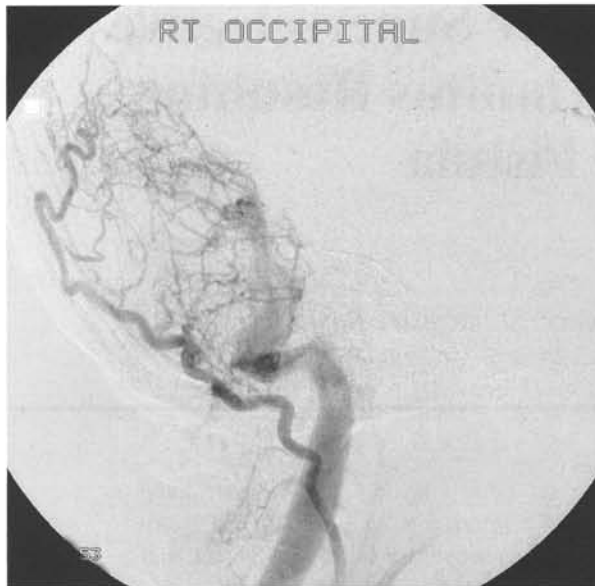


Figure 1. Superselective carotid angiography demonstrating the arteriovenous fistulous malformation supplied by the occipital artery. The arterial and venous phases are demonstrated simultaneously.

DISCUSSION

Pulsatile tinnitus demands a thorough examination and investigation. Clinical examination should include palpation of the skull and auscultation of the neck, skull, and mastoid process. Although benign (idiopathic) intracranial hypertension has been reported to be the most frequent diagnosis [1,2], ascribing this diagnosis of exclusion in the face of true intracranial vascular malformation can have catastrophic consequences [3]. Pulsatile tinnitus should always raise the consideration of a vascular abnormality [4] (a tumor, a congenital anomaly, or malformation).

Pulsatile tinnitus may be subjective or both subjective and objective. A dural AVF (DAVF) is the most frequent cause of objective pulsatile tinnitus in a patient with a normal otoscopic examination [5], and pulsatile tinnitus is the most common presenting symptom of DAVF [3]. Although one study of patients with subjective pulsatile tinnitus and a normal otoscopic examination found no MRI abnormalities to explain the tinnitus [6], the possibility of vascular tumor or malformation can be confirmed only by angiography. Weissmann and Hirsch [2] stated that patients with only subjective pulsatile tinnitus usually have no imaging abnormalities and therefore did not include angiography in their decision tree for imaging of subjective tinnitus. Both Morrison [7] and our case report showed that this is not always true. Because DAVF is often invisible on com-

Table 1. Grades of Venous Restrictive Disease Associated with Transverse-Sigmoid Sinus Dural Arteriovenous Fistulas

Grade	Antegrade Venous Drainage	Retrograde Venous Drainage	Cortical Venous Drainage
1	Normal	Absent	Absent
2	Diminished	Present	Present or absent
3	Absent	Present	Present
4	Absent	Absent	Present

puted tomography and MRI studies [8], in the presence of a convincing history of strongly pulsatile tinnitus and absence of apparent ear disease or hearing loss, early angiography is an important diagnostic option should magnetic resonance angiography be negative [2,3,7], particularly in situations of objective bruit.

Transverse-sigmoid sinus DAVFs (TSDAVFs) are classified on the basis of the presence or absence of cortical venous drainage and antegrade venous drainage. Four grades of venous restrictive disease were defined (Table 1) [4]. Grade 1 is characterized by normal antegrade venous drainage without venous restriction or cortical venous drainage. Shah et al. [3] and Halbach et al. [9] advocated using intermittent occipital or carotid artery compression therapy for initial treatment of grade 1 lesions, with repeat angiography at 6 months or sooner, as symptoms warrant. If the fistula persisted, transarterial embolization would be performed, and repeat angiography would be obtained 1–2 months after embolization. This is because transverse-sigmoid sinus DAVF is a dynamic disease that can progress from minor venous restrictive disease to more severe venous outflow obstruction associated with significant morbidity and death. In the series by Shah et al. [3], three of five patients were successfully treated with compression therapy. The other two had successful transarterial embolization using polyvinyl alcohol particles.

CONCLUSION

In our case report, the spontaneous resolution of grade 1 transverse-sigmoid sinus DAVF after diagnostic superselective angiography is interesting. As far as we can tell, it has not been reported previously. It probably indicates thrombosis of the fistula, but the extent (if any) to which the angiography contributed to the outcome is unclear.

REFERENCES

1. Sismanis A. Pulsatile tinnitus: A 15 year experience. *Am J Otol* 19:472–477, 1998.

2. Weissmann JL, Hirsch BE. Imaging of tinnitus: A review. *Radiology* 216:342–349, 2000.
3. Shah SB, Lalwani AK, Dowd CF. Transverse-sigmoid sinus dural arteriovenous fistulas presenting as pulsatile tinnitus. *Laryngoscope* 109(1):54–58, 1999.
4. Saeed SR, Hinton AE, Ramsden RT, Lye RH. Spontaneous dissection of the intrapetrous internal carotid artery. *J Laryngol Otol* 104:491–493, 1990.
5. Roy D, Lavigne F, Raymond J. Pulsatile tinnitus and dural arteriovenous fistula of the transverse sinus. *J Otolaryngol* 22:409–412, 1993.
6. Dietz RR, Davis WL, Harnsberger HR, et al. MR imaging and MR angiography in the evaluation of pulsatile tinnitus. *AJNR Am J Neuroradiol* 15:879–889, 1994.
7. Morrison GA. Pulsatile tinnitus and dural arteriovenous malformation. *J Laryngol Otol* 103:1073–1075, 1989.
8. Koenigsberg RA. Spontaneous pulsatile tinnitus secondary to a dural malformation not visualized by magnetic resonance angiography. *Clin Imaging* 20:95–98, 1996.
9. Halbach VV, Higashida RT, Hieshima GB, et al. Dural fistulas involving the transverse and sigmoid sinus: Results of treatment in 28 patients. *Radiology* 163:443–447, 1987.